




Contents lists available at ScienceDirect

## Current Research in Parasitology &amp; Vector-Borne Diseases

journal homepage: [www.sciencedirect.com/journal/current-research-in-parasitology-and-vector-borne-diseases](http://www.sciencedirect.com/journal/current-research-in-parasitology-and-vector-borne-diseases)Update on infections with *Thelazia callipaeda* in European wildlife and a report in a red fox, *Vulpes vulpes*, in PortugalAna Filipa Lopes<sup>a</sup>, Mariana Ribeiro Ferreira<sup>a</sup>, Beatriz do Vale<sup>b</sup>, Marlene Santos<sup>c</sup>, Inês Silveira<sup>a</sup>, Sofia Claudino<sup>a</sup>, Manuel Martins<sup>b,d</sup>, Telma Brida<sup>b</sup>, Luís Figueira<sup>b,d</sup>, Luís Cardoso<sup>e,f,\*</sup>, Ana Patrícia Lopes<sup>e,f</sup>, Ana Cláudia Coelho<sup>e,f</sup>, Manuela Matos<sup>c</sup>, Ana Cristina Matos<sup>b,g</sup><sup>a</sup> Centre for the Study and Recovery of Wild Animals (CERAS), Quercus ONGA, Castelo Branco, Portugal<sup>b</sup> School of Agriculture, Polytechnic University of Castelo Branco (ESA-IPCB), Castelo Branco, Portugal<sup>c</sup> Centre for the Research and Technology of Agro-Environmental and Biological Sciences (CITAB), UTAD, Vila Real, Portugal<sup>d</sup> Quality of Life in the Rural World (Q-RURAL), Polytechnic University of Castelo Branco, Castelo Branco, Portugal<sup>e</sup> Animal and Veterinary Research Centre (CECAV), Associate Laboratory for Animal and Veterinary Sciences (AL4Animals), University of Trás-os-Montes e Alto Douro, Vila Real, Portugal<sup>f</sup> Department of Veterinary Sciences, School of Agrarian and Veterinary Sciences (ECAV), UTAD, Vila Real, Portugal<sup>g</sup> Research Centre for Natural Resources, Environment and Society (CERNAS), Polytechnic University of Castelo Branco, Castelo Branco, Portugal

## ARTICLE INFO

## Keywords:

Eyeworm  
One Health  
Portugal  
Red fox  
*Thelazia callipaeda*  
Vector-borne zoonosis

## ABSTRACT

*Thelazia callipaeda*, also known as the “oriental eye worm”, is a zoonotic parasitic nematode with a wide range of hosts, particularly wild and domestic carnivores, but also lagomorphs and humans. Currently, ocular thelaziosis presents an expanding distribution range throughout Europe, including Portugal. This study provides an update on *T. callipaeda* infection reports (30 studies) in European wildlife comprising 54 host-locality records in 10 host species from nine European countries. The prevalence of *T. callipaeda* varied widely, with ranges from around 1% in red foxes and European hares to almost 50% in red foxes. The lowest mean intensity was 2.7 nematodes/host in European wildcats and the highest was 38.0 nematodes/host in wolves. In addition, a massive infection with *T. callipaeda* in a juvenile male red fox from eastern-central Portugal is also described, representing the southernmost report in a wild animal in this country. A total of 188 nematodes (139 females and 49 males) were collected from both eyes and were submitted to morphological and molecular characterization. Collected nematodes were morphologically identified as *T. callipaeda*. Given the endemicity of *T. callipaeda* in eastern-central Portugal, surveillance system should be implemented to monitor its presence among wild and domestic animals.

## 1. Introduction

*Thelazia callipaeda* (Spirurida: Thelaziidae), also called the “oriental eyeworm”, is a vector-borne, zoonotic nematode parasite with a large spectrum of hosts (Anderson, 2000; Otranto and Traversa, 2005; do Vale et al., 2020), both domestic (Rodrigues et al., 2012; Vieira et al., 2012; Pimenta et al., 2013; Soares et al., 2013; Maia et al., 2016; Rolbiecki et al., 2021) and wild animals, notably including red foxes.

This eyeworm infects the conjunctival sac, tear glands, tear ducts and nictitating membrane, and can be responsible for various ophthalmological clinical signs (Otranto and Traversa, 2005; do Vale et al., 2020).

In Europe, the large-sized drosophilid fruit fly *Phortica variegata* Fallén, 1823 (Drosophilidae: Steganinae) was confirmed as the nematode intermediate host (Otranto et al., 2006; Marino et al., 2018). This non-biting fly ingests the larvae whilst feeding on the host’s lachrymal secretions (Otranto et al., 2006; Marino et al., 2018).

Currently, ocular thelaziosis presents an expanding distribution range throughout Europe (do Vale et al., 2019). During the last nearly two decades, human cases of thelaziosis were detected in patients from Italy and France (Otranto and Dutto, 2008), Serbia (Tasić-Otašević et al., 2016), Croatia (Paradžik et al., 2016), Germany (Dolff et al., 2020), Spain (Fuentes et al., 2012; López Medrano et al., 2015);

\* Corresponding author. Animal and Veterinary Research Centre (CECAV), Associate Laboratory for Animal and Veterinary Sciences (AL4Animals), University of Trás-os-Montes e Alto Douro, Vila Real, Portugal.

E-mail address: [lcardoso@utad.pt](mailto:lcardoso@utad.pt) (L. Cardoso).

<https://doi.org/10.1016/j.crpvbd.2024.100211>

Received 25 June 2024; Received in revised form 21 August 2024; Accepted 22 August 2024

Available online 23 August 2024

2667-114X/© 2024 Published by Elsevier B.V. This is an open access article under the CC BY-NC-ND license (<http://creativecommons.org/licenses/by-nc-nd/4.0/>).

Martínez-Sánchez et al., 2021) and Portugal (Morgado et al., 2022). Wild animals have been involved in the epidemiological cycle of *Thelazia* spp., contributing to the introduction and dissemination among animals in non-endemic regions. Foxes should be considered the main reservoir of thelaziosis in European wildlife (Otranto et al., 2009; Otranto and Dantas-Torres, 2015).

In Portugal, the first cases of infection with this eyeworm in red foxes (*Vulpes vulpes*) were reported in the northern and eastern-central regions of the country (Sargo et al., 2014). The present study provides an update on the reports of *T. callipaeda* in European wildlife and describes a massive infection in a red fox from eastern-central Portugal, representing the southernmost report from a wild animal in this country and one of the greatest worms per host count ever.

## 2. Materials and methods

### 2.1. Update on *T. callipaeda* in European wildlife

An update on studies, reports and/or cases of *T. callipaeda* infection in European wildlife has been carried out based on six new studies (Diakou et al., 2021; Bezerra-Santos et al., 2022; Cotuțiu et al., 2022; Papadopoulos et al., 2022; Bertos et al., 2023; Deak et al., 2023) published after the most recent review by do Vale et al. (2020). Values for prevalence (proportion of infected hosts in %) and mean intensity (mean number of nematodes per infected individual host) are given as published or calculated (for total sample size  $\geq 8$  animals and sample size of infected animals  $\geq 3$ ) from the data in the original publications whenever possible. European records of *T. callipaeda* in red foxes were georeferenced according to the World Geodetic System 1984 (WGS 84).

### 2.2. New record of *T. callipaeda*

A juvenile male red fox (*V. vulpes*), approximately 6 months old, was admitted to the Wildlife Study and Rehabilitation Centre of the National Association for Nature Conservation (CERAS – Quercus), located in the municipality of Castelo Branco, in eastern-central Portugal. The wild animal was found severely debilitated on October 11, 2021, in Covilhã (Gibaltar, Teixoso) (40.3°N, 7.4°W).

Physical examination revealed poor body condition, weight of 1.686 kg, high degree of dehydration (9–12%), prostration, and ectoparasites (*Ctenocephalides felis* fleas). Both eyes were closed, and the eyelids were covered with an abundant purulent discharge (Fig. 1). Traces of blood were found in the left eye, on the medial corner. Both eyes presented a large number of transparent to whitish filamentous and mobile adult worms under the third eyelid and in the conjunctival sac. Conjunctival hyperemia was present in both eyes, with a small corneal scar on the left eye. The eyes were cleaned with sterile physiological saline solution (NaCl 0.9%) and all worms removed manually once daily for 3 days, and then stored in 70% ethanol.

The therapeutic approach included topic application of 1% fusicidic acid (Fucithalmic®; Amdipharm, Dublin, Ireland) BID for 7 days and diclofenac (Voltaren®; Novartis, Baden, Germany) BID for 3 days, external deworming with fipronil and permethrin (Frontline Tri-act®; Boehringer Ingelheim Animal Health, Ingelheim, Germany) plus the combination of imidacloprid 10% and moxidectin 2.5% (Advocate®; Elanco Animal Health, Leverkusen, Germany) pour on, and systemic treatment with enrofloxacin (Baytril®; Elanco Animal Health, Germany; and Enroxal®; HCS bvba, Edegem, Belgium) 5 mg/kg, SID, firstly subcutaneous (SC) and then per os (PO) for 7 days, meloxicam (Melovem®; Dopharma, Raamsdonksveer, The Netherlands) 0.2 mg/kg, SID, firstly SC and then PO for 3 days, and intravenous fluids specifically lactated Ringers solution, 10% dextrose solution and a multivitamins and minerals solution (Duphalyte®; Parsippany, NJ, USA).



Fig. 1. Admission at the Wildlife Study and Rehabilitation Centre (CERAS) of a juvenile male red fox (*Vulpes vulpes*).

### 2.3. Molecular analysis

Eight nematodes were sent to the Department of Genetics and Biotechnology, University of Trás-os-Montes e Alto Douro (Vila Real, Portugal). These worms were used for molecular identification. DNA was extracted from the eight nematodes using DNA NZY Tissue gDNA Isolation Kit (NZYtech, Lisbon, Portugal). A partial sequence (689 bp) of the mitochondrial cytochrome c oxidase subunit 1 gene (*cox1*) was amplified by polymerase chain reaction (PCR) using the primers NTF and NTR (Otranto and Traversa, 2005). The fragment was successfully amplified from seven worms and the four with the most intense bands were selected for sequencing. Amplified products from the PCR were purified using ExoSAP-IT™ PCR Product Cleanup Reagent (Applied Biosystems, Foster City, CA, USA) according to the manufacturer's instructions. Sequencing was performed in an Applied Biosystems 3730xl DNA Analyzer (Stab Vida, Caparica, Portugal). Amplicons were sequenced in both directions and sequence alignment was made using MEGA version 11 (Tamura et al., 2021). The consensus sequences were obtained with BioEdit software and sequence similarity was studied using the BLASTN program available on the National Center for Biotechnology Information database (NCBI; <https://blast.ncbi.nlm.nih.gov/Blast.cgi>).

## 3. Results and discussion

To date, infections with *T. callipaeda* have been reported in 30 studies for ten wild vertebrate host species, i.e. red fox, wolf, beech marten, European hare, European wildcat, golden jackal, wild rabbit, Eurasian badger, brown bear and a lion in a zoological garden in Romania, comprising 54 host-locality records in nine European countries (Table 1).

The relative majority of reports have been from red foxes (Fig. 2), with 25 host-locality records in eight countries, a circumstance that may be related to the fact that this is the most abundant terrestrial wild

**Table 1**  
Reports on *Thelazia callipaeda* infection in European wildlife.

Host	Country	Locality (n)	n/N	Prevalence (%)	No. of worms	Intensity		Reference
						Range	Mean ± SD	
Red fox ( <i>Vulpes vulpes</i> )	Switzerland	Ticino canton	7/126	5.6	27	1–10	[3.9]	Malacrida et al. (2008)
	Italy	Basilicata region	37/75	49.3	139	1–13	3.8 ± 2.0	Otranto et al. (2009)
	Spain	Cáceres Province	2/–	–	14	2–12	[7.0 ± 7.1]	Calero-Bernal et al. (2013)
	Bosnia and Herzegovina	Eastern, northeastern, northern and central Bosnia and Herzegovina	51/184	27.7	364	1–50	8.08 ± 9.41	Hodžić et al. (2014)
	Portugal	Montalegre municipality (n = 1); Sabugal municipality (n = 2)	3/–	–	7, 10	–	[5.7]	Sargo et al. (2014)
	Serbia	Belgrade (n = 2); Požarevac (n = 1)	3/–	–	7, 11, 5	[5–11]	[7.7 ± 3.1]	Pavlović et al. (2017)
	Slovakia	Košice (n = 6); Trenčín (n = 1)	7/523	1.3	45	2–12	6.4 ± 4.4	Cabanová et al. (2018)
	Romania	Arad, Bihor, Cluj, Gorj, Hunedoara, Maramureş, Mureş, Sălaj, Satu-Mare and Timiş counties	151/514	29.4	3350	1–192	23.2	Ionică et al. (2018)
	Portugal	Covilhã	1/–	–	188	–	–	Present study
	Italy	Basilicata region	3/–	–	3, 15, 96	[3–96]	[38.0 ± 50.6]	Otranto et al. (2007)
Wolf ( <i>Canis lupus</i> )	Italy	Basilicata region	1/2	–	2	–	–	Otranto et al. (2009)
	Romania	Pianu de Sus (Alba County)	1/13	7.7	4	–	–	Mihalca et al. (2016)
	Serbia	Negotin (n = 1); Sjenica (n = 1); Jagodina (n = 1); Braničevo (n = 2); Ražanj (n = 1); Despotovac (n = 1); Svrlijig (n = 1)	8/21	38.1	21, 12, 7, 132, 70, 35, 8, 4	[4–132]	[36.1 ± 44.4]	Gajić et al. (2019)
	Spain	Guadalajara Province	1/–	–	42	–	–	Nájera et al. (2020)
	Greece	Florina Prefecture	13/–	–	9, 10, 7, 16, 13, 6, 8, 13, 10, 15, 8, 7, 9	[6–16]	[10.1 ± 3.2]	Papadopoulos et al. (2022)
	Italy	Piedmont region (n = 1); Tuscany region (n = 2)	3/–	–	41, 8, 7	–	[18.7 ± 19.3]	Bezerra-Santos et al. (2022)
	Italy	Basilicata region	3/22	13.6	15	3–6	5.0 ± 1.7	Otranto et al. (2009)
Beech marten ( <i>Martes foina</i> )	Portugal	Vila Real municipality	1/–	–	1	–	–	Seixas et al. (2018)
	Romania	Eastern Romania	1/13	7.7	1	–	–	Ionică et al. (2019)
European hare ( <i>Lepus europaeus</i> )	Italy	Basilicata region	3/13	23.1	17	3–11	5.7 ± 4.6	Otranto et al. (2009)
	Romania	Continental (n = 3) and steppic (n = 1) ecoregions	4/326	1.2	1, 4, 9, 70	[1–70]	[21.0 ± 32.8]	Cotutiu et al. (2022)
European wildcat ( <i>Felis silvestris</i> )	Italy	Basilicata region	3/8	37.5	16	3–7	5.3 ± 2.1	Otranto et al. (2009)
	Romania	Mesteacanu (Sălaj County)	1/9	11.1	2	–	–	Mihalca et al. (2016)
	Greece	Mainland and Crete	2/23	8.7	–	–	–	Diakou et al. (2021)
	Spain	Sierra Arana (Granada Province)	3/17	17.6	2, 2, 3	[1–3]	[2.7 ± 0.6]	Bertos et al. (2023)
Golden jackal ( <i>Canis aureus</i> )	Romania	Ostrovu Mare (Mehedinți County)	1/64	1.6	70	–	–	Mihalca et al. (2016)
Wild rabbit ( <i>Oryctolagus cuniculus</i> )	Portugal	Vilar de Ossos (Vinhais municipality)	2/2	–	6	3–3	–	Gama et al. (2016)
Eurasian badger ( <i>Meles meles</i> )	Romania	Western Romania	1/55	1.8	33	–	–	Ionică et al. (2019)
Brown bear ( <i>Ursus arctos</i> )	Greece	Florina prefecture	8/30	26.7	11, 3, 4, 5, 7, 2, 3, 5	[2–11]	[5.0 ± 2.9]	Papadopoulos et al. (2022)
Lion ( <i>Panthera leo</i> )	Romania	Reșița Zoo (Caraș-Severin County)	1/–	–	4	–/–	–	Deak et al. (2023)

Note: The mean ± SD values calculated from the original data for the present update are displayed in square brackets.

Abbreviations: n, number of infected animals; N, number of examined animals; –, not available/not computable; SD, standard deviation.

carnivore in the world (Basto et al., 2016). For wolves, 14 host-locality-time reports (2 reports different in time from the same locality; Otranto et al., 2007, 2009) in five countries have been recorded. Therefore, from a One Health perspective, foxes and also wolves can be considered appropriate sentinels of *T. callipaeda* infection to both humans and other wild and domestic animals.

Regarding the ten wild host species, studies/records from

Mediterranean and western European countries (Greece, Italy, Portugal, Spain and Switzerland) were slightly more frequent ( $n = 18$  versus  $n = 12$ ) than from eastern European countries (Bosnia and Herzegovina, Romania, Serbia and Slovakia). For red foxes, four studies have been carried out in Italy, Portugal, Spain and Switzerland, and another four studies in Bosnia and Herzegovina, Slovakia, Romania and Serbia. For wolves, five studies have been carried in Greece, Italy and Spain, and

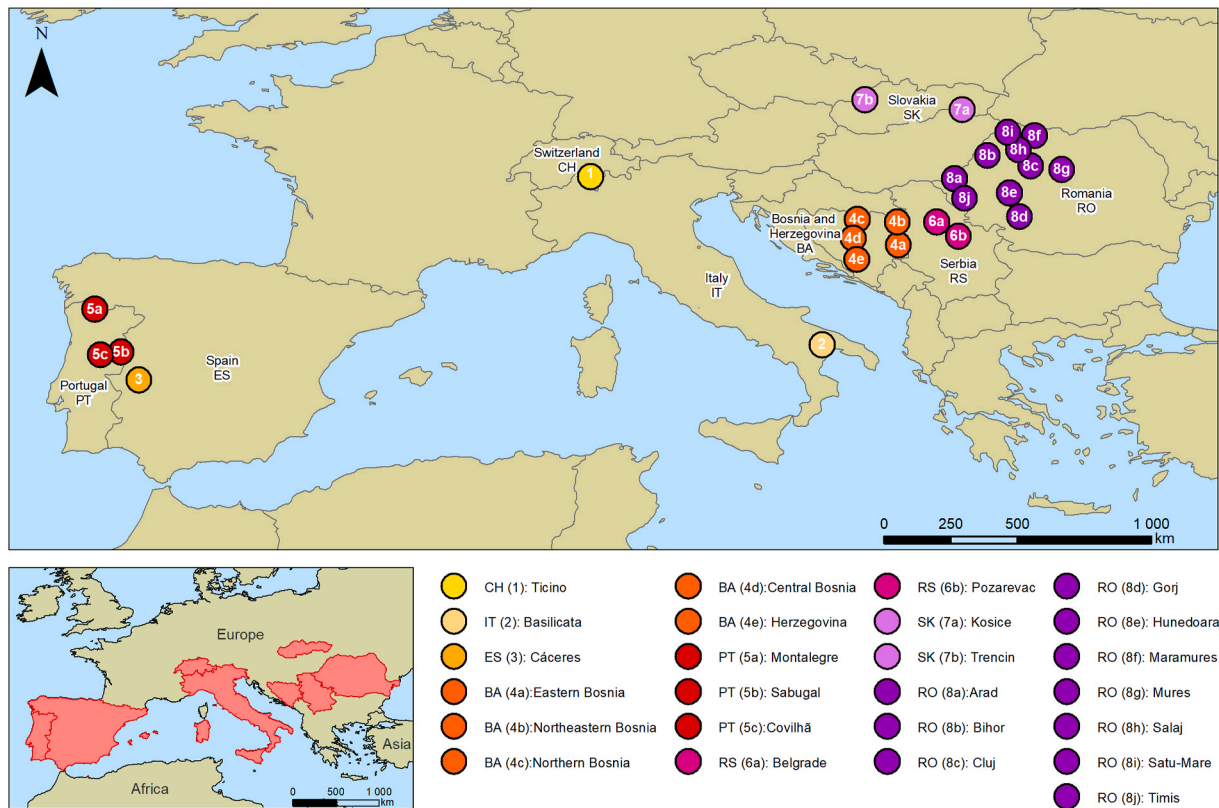


Fig. 2. Map of approximate European locations from where red foxes (*Vulpes vulpes*) infected with *Thelazia callipaeda* have been reported. The map was constructed using ArcGIS Desktop v10.8.1 (ESRI, 2020), and records were georeferenced according to the World Geodetic System 1984 (WGS 84). For additional details, see Table 1.

two studies in Romania and Serbia (Table 1).

Whenever computable, the prevalence of *T. callipaeda* varied widely, ranging from around 1% in red foxes in Slovakia and European hares in Romania to almost 50% in red foxes in Italy (Table 1). Wide prevalence ranges were also observed in most host species as follows: (i) in red foxes, from 1.3% in Slovakia (Košice and Trenčin; Čabanová et al., 2018) to 49.3% in Italy (Basilicata region; Otranto et al., 2009); (ii) in wolves, from 7.7% in Romania (Pianu de Sus, Alba County; Mihalca et al., 2016) to 38.1% in Serbia (seven localities; Gajić et al., 2019); (iii) in beech martens, from 7.7% in Romania (eastern Romania; Ionică et al., 2019) to 13.6% in Italy (Basilicata region; Otranto et al., 2009); (iv) in European hares, from 1.2% in Romania (continental and steppic ecoregions; Cotuțiu et al., 2022) to 23.1% in Italy (Basilicata region; Otranto et al., 2009); and (v) in European wildcats, from 8.7% in Greece (Diakou et al., 2021) to 37.5% in Italy (Basilicata region; Otranto et al., 2009). Other reports have revealed single prevalence values of: (i) 1.6% in golden jackals in Romania (Ostrovu Mare, Mehedinți County; Mihalca et al., 2016); (ii) 1.8% in Eurasian badgers also in Romania (western Romania; Ionică et al., 2019); and (iii) 26.7% in brown bears in Greece (Florina prefecture; Papadopoulos et al., 2022).

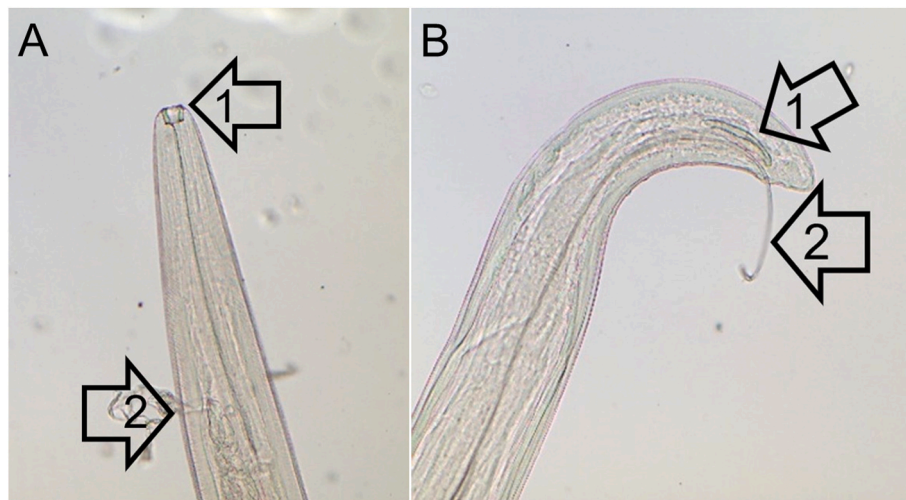Mean intensity values also ranged widely with the lowest mean intensity of 2.7 nematodes/host recorded in European wildcats from Spain and the highest mean intensity of 38.0 nematodes/host in wolves from Italy (Table 1). Mean intensity ranges by host species were as follows: (i) in red foxes, from 3.8 nematodes/host in Italy (Basilicata region; Otranto et al., 2009) to 23.2 nematodes/host in Romania (10 localities, Ionică et al., 2019); (ii) in wolves, from 10.1 nematodes/host in Greece (Florina prefecture; Papadopoulos et al., 2022) to 38.0 nematodes/host in Italy (Basilicata region; Otranto et al., 2007); (iii) in European hares, from 5.7 nematodes/host in Italy (Basilicata region; Otranto et al., 2009) to 21.0 nematodes/host in Romania (continental and steppic ecoregions; Cotuțiu et al., 2022); and (iv) in European wildcat, from 2.7

nematodes/host in Spain (Sierra Arana, Granada province; Bertos et al., 2023) to 5.3 nematodes/host in Italy (Basilicata region; Otranto et al., 2009). The intensity value from a unique host study was 5.0 nematodes/host in eight brown bears from Greece (Table 1; Florina prefecture; Papadopoulos et al., 2022).

In the present study, a total of 188 nematodes were recovered from both eyes of *V. vulpes* (106 from the left eye and 82 from the right eye), which represent one of the highest numbers found in wild (Table 1) and also domestic animals. Collected nematodes were morphologically identified as 139 females and 49 males of *T. callipaeda* (Fig. 3). The four partial *cox1* sequences selected had 98.1–98.6% nucleotide identity to the corresponding *T. callipaeda* gene in NCBI Core nucleotide database, and have been deposited in GenBank (accession numbers PQ203220–PQ203223).

In Portugal, infections with *T. callipaeda* in both domestic and wild animals have been reported mainly in the North of the country, above the Douro River (Rodrigues et al., 2012; Vieira et al., 2012; Pimenta et al., 2013; Sargo et al., 2014; Gama et al., 2016; Seixas et al., 2018). The presence of *T. callipaeda* in the district of Castelo Branco could mean a spread of the nematode. However, cases of thelaziosis caused by *T. callipaeda* in east-central Portugal have already been reported in red foxes (Sargo et al., 2014), dogs and cats (Maia et al., 2016), and in a human (Morgado et al., 2022). These facts support the endemicity of *T. callipaeda* in eastern-central Portugal.

The identification of *T. callipaeda*, but also other *Thelazia* spp., is important, in epidemiological terms, because the district of Castelo Branco has a large economic component sustained in agriculture, especially in the production of large and small ruminants. Moreover, it is well known for its hunting areas and considerable presence of red foxes, including in urban areas. Therefore, the risk of increased cases occurrence in animals and humans due to the presence of infected hosts (vertebrates and the fruit fly *P. variegata*) must be considered and



**Fig. 3.** A Adult female of *Thelazia callipaeda*: anterior extremity with buccal capsule (arrow 1) and vulva (arrow 2). B Adult male of *T. callipaeda*: posterior extremity with short spicule (arrow 1) and long spicule (arrow 2).

evaluated.

#### 4. Conclusions

The present study updated the information on *T. callipaeda* infections in ten wild species from nine European countries. The prevalence of *T. callipaeda* varied widely, with ranges from around 1% in red foxes and European hares to almost 50% in red foxes. The lowest mean intensity was 2.7 nematodes/host in European wildcats and the highest was 38.0 nematodes/host in wolves. The first case of thelaziosis in a red fox from the district of Castelo Branco is also reported, highlighting the endemicity of *T. callipaeda* in the eastern-central area of Portugal. There is a need for a surveillance system that monitors *Thelazia* spp. in domestic and wild animals. Attention should also be given to infection in humans, due to the zoonotic character of *T. callipaeda*.

#### Funding

This work was supported by projects UIDB/00772/2020 (<https://doi.org/10.54499/UIDB/00772/2020>), UIDB/04033/2020 (<https://doi.org/10.54499/UIDB/04033/2020>), LA/P/0059/2020 and LA/P/0126/2020, all funded by the Portuguese Foundation for Science and Technology (FCT).

#### Ethical approval

All procedures complied with the Portuguese legislation for the protection of animals used for scientific purposes (i.e. Decree-Law no. 113/2013, of August 7, 2013), which transposes European legislation (i.e. Directive, 2010/63/EU of the European Parliament and the Council, of September 22, 2010).

#### CRediT authorship contribution statement

**Ana Filipa Lopes:** Conceptualization, Investigation, Writing – original draft, Writing – review & editing. **Mariana Ribeiro Ferreira:** Conceptualization, Investigation, Writing – original draft, Writing – review & editing. **Beatriz do Vale:** Formal analysis, Writing – review & editing, Visualization. **Marlene Santos:** Investigation. **Inês Silveira:** Investigation. **Sofia Claudino:** Investigation. **Manuel Martins:** Formal analysis. **Telma Brida:** Investigation. **Luís Figueira:** Formal analysis. **Luís Cardoso:** Formal analysis, Writing – review & editing, Visualization. **Ana Patrícia Lopes:** Formal analysis, Resources. **Ana Cláudia Coelho:** Formal analysis, Writing – review & editing, Visualization.

**Manuela Matos:** Methodology, Validation. **Ana Cristina Matos:** Formal analysis, Visualization, Supervision.

#### Declaration of competing interests

The authors declare that they have no known competing financial interests or personal relationships that could have appeared to influence the work reported in this paper. Given their role as Guest Editors, Ana Cláudia Coelho, Ana Patrícia Lopes and Luís Cardoso had no involvement in the peer review of this article and have no access to information regarding its peer review. Full responsibility for the editorial process for this article was delegated to Professor Aneta Kostadinova (Editor-in-Chief).

#### Data availability

The data collected and analysed during the study are provided within the article. The newly generated sequences were deposited in the GenBank database under the accession numbers PQ203220-PQ203223.

#### Acknowledgments

We thank Eng. Teresa Coutinho, Laboratory of Parasitology, Department of Veterinary Sciences, ECAV, UTAD, for preparing and photographing eyeworms, and Eng. Natália Roque, GIS Laboratory, ESA-IPCB, for designing the map.

#### References

- Anderson, R.C., 2000. *Nematode Parasites of Vertebrates: Their Development and Transmission*, 2nd ed. CABI Publishing, Guilford, UK, pp. 404–407.
- Basto, M.P., Santos-Reis, M., Simões, L., Grilo, C., Cardoso, L., Cortes, H., et al., 2016. Assessing genetic structure in common but ecologically distinct carnivores: The stone marten and red fox. *PLoS One* 11, e0145165. <https://doi.org/10.1371/journal.pone.0145165>.
- Bertos, E., Sánchez-Cerdá, M., Virgós, E., Gil-Sánchez, J.M., Moleón, M., 2023. *Thelazia callipaeda* as a potential new threat to European wildcats: Insights from an eco-epidemiological study. *Vet. Res. Commun.* 47, 2153–2160. <https://doi.org/10.1007/s11259-023-10071-8>.
- Bezerra-Santos, M.A., Moroni, B., Mendoza-Roldan, J.A., Perrucci, S., Cavicchio, P., Cordon, R., et al., 2022. Wild carnivores and *Thelazia callipaeda* zoonotic eyeworms: A focus on wolves. *Int. J. Parasitol. Parasites Wildl.* 17, 239–243. <https://doi.org/10.1016/j.ijppaw.2022.03.005>.
- Čabanová, V., Miterpáková, M., Oravec, M., Hurníková, Z., Jerg, S., Nemčíková, G., Červenská, M.B., 2018. Nematode *Thelazia callipaeda* is spreading across Europe. The first survey of red foxes from Slovakia. *Acta Parasitol.* 63, 160–166. <https://doi.org/10.1515/ap-2018-0018>.

- Calero-Bernal, R., Otranto, D., Pérez-Martín, J.E., Serrano, F.J., Reina, D., 2013. First report of *Thelazia callipaeda* in wildlife from Spain. *J. Wildl. Dis.* 49, 458–460. <https://doi.org/10.7589/2012-10-268>.
- Cotutiu, V.-D., Mihalca, A.D., Holówka, K.A., Ionică, A.M., Cazan, C.D., Gherman, C.M., 2022. European hares, *Lepus europaeus*, represent a reservoir host for *Thelazia callipaeda* in Romania. *Pathogens* 11, 1225. <https://doi.org/10.3390/pathogens11111225>.
- Deak, G., Ionică, A.M., Mihalca, A.D., 2023. First report of *Thelazia callipaeda* Railliet & Henry, 1910 in a Zoo lion (*Panthera leo*) (Linnaeus, 1758) from Romania. *Vet. Res. Commun.* 47, 2173–2177. <https://doi.org/10.1007/s11259-023-10097-y>.
- Diakou, A., Migli, D., Dimzas, D., Morelli, S., Di Cesare, A., Youlatos, D., et al., 2021. Endoparasites of European wildcats (*Felis silvestris*) in Greece. *Pathogens* 10, 594. <https://doi.org/10.3390/pathogens10050594>.
- do Vale, B., Lopes, A.P., da Conceição Fontes, M., Silvestre, M., Cardoso, L., Coelho, A.C., 2020. Systematic review on infection and disease caused by *Thelazia callipaeda* in Europe: 2001–2020. *Parasite* 27, 52. <https://doi.org/10.1051/parasite/2020048>.
- do Vale, B., Lopes, A.P., da Conceição Fontes, M., Silvestre, M., Cardoso, L., Coelho, A.C., 2019. Thelaziosis due to *Thelazia callipaeda* in Europe in the 21st century – a review. *Vet. Parasitol.* 275, 108957. <https://doi.org/10.1016/j.vetpar.2019.108957>.
- Dolf, S., Kehrmann, J., Eisermann, P., Dalbah, S., Tappe, D., Rating, P., 2020. Case report: *Thelazia callipaeda* eye infection: the first human case in Germany. *Am. J. Trop. Med. Hyg.* 102, 350–351. <https://doi.org/10.4269/ajtmh.19-0483>.
- ESRI, 2020. ArcGIS Desktop v10.8.1 (Version 10.8.1). Environmental Systems Research Institute. <https://www.esri.com/en-us/arcgis/products/arcgis-desktop/resources>.
- Fuentes, I., Montes, L., Saugar, J.M., Latrofa, S., Gárate, T., Otranto, D., 2012. Thelaziosis in humans, a zoonotic infection, Spain, 2011. *Emerg. Infect. Dis.* 18, 2073–2075. <https://doi.org/10.3201/eid1812.120472>.
- Gajić, B., Bugarski-Stanojević, V., Penezić, A., Kurućki, M., Bogdanović, N., Čirović, D., 2019. First report of eyeworm infection by *Thelazia callipaeda* in gray wolf (*Canis lupus*) from Serbia. *Parasitol. Res.* 118, 3549–3553. <https://doi.org/10.1007/s00436-019-06519-z>.
- Gama, A., Pires, I., Canado, M., Coutinho, T., Lopes, A.P., Latrofa, M.S., et al., 2016. First report of *Thelazia callipaeda* infection in wild European rabbits (*Oryctolagus cuniculus*) in Portugal. *Parasites Vectors* 9, 236. <https://doi.org/10.1186/s13071-016-1526-1>.
- Hodžić, A., Latrofa, M.S., Annoscia, G., Alić, A., Beck, R., Lia, R.P., et al., 2014. The spread of zoonotic *Thelazia callipaeda* in the Balkan area. *Parasites Vectors* 7, 352. <https://doi.org/10.1186/1756-3305-7-352>.
- Ionică, A.M., Deak, G., D'Amico, G., Stan, G.F., Chișamera, G.B., Constantinescu, I.C., et al., 2019. *Thelazia callipaeda* in mustelids from Romania with the European badger, *Meles meles*, as a new host for this parasite. *Parasites Vectors* 12, 370. <https://doi.org/10.1186/s13071-019-3631-4>.
- Ionică, A.M., Deak, G., Matei, I.A., D'Amico, G., Cotuțiu, V.D., Gherman, C.M., Mihalca, A.D., 2018. *Thelazia callipaeda*, an endemic parasite of red foxes (*Vulpes vulpes*) in western Romania. *J. Wildl. Dis.* 54, 829–833. <https://doi.org/10.7589/2017-10-251>.
- López Medrano, R., Guerra Calleja, G., Díez Morrondo, C., Panadero Fontán, R., 2015. Thelaziosis ocular, una zoonosis emergente en España. *Med. Clínica* 145, 317–318. <https://doi.org/10.1016/j.medcli.2015.02.014>.
- Maia, C., Catarino, A.L., Almeida, B., Ramos, C., Campino, L., Cardoso, L., 2016. Emergence of *Thelazia callipaeda* infection in dogs and cats from east-central Portugal. *Transbound. Emerg. Dis.* 63, 416–421. <https://doi.org/10.1111/tbed.12284>.
- Malacrida, F., Hegglin, D., Bacciarini, L., Otranto, D., Nägeli, F., Nägeli, C., et al., 2008. Emergence of canine ocular thelaziosis caused by *Thelazia callipaeda* in southern Switzerland. *Vet. Parasitol.* 157, 321–327. <https://doi.org/10.1016/j.vetpar.2008.07.029>.
- Marino, V., Gálvez, R., Colella, V., Sarquis, J., Checa, R., Montoya, A., et al., 2018. Detection of *Thelazia callipaeda* in *Phortica variegata* and spread of canine thelaziosis to new areas in Spain. *Parasites Vectors* 11, 195. <https://doi.org/10.1186/s13071-018-2773-0>.
- Martínez-Sánchez, M.I., Bolívar-de-Miguel, G., Cuadros-González, J., Rubio González, J. M., 2021. Ocular thelaziosis: A case report of an emerging zoonosis. *Am. J. Ophthalmol. Case Rep.* 22, 101045. <https://doi.org/10.1016/j.ajoc.2021.101045>.
- Mihalca, A.D., Ionică, A.M., D'Amico, G., Daskalaki, A.A., Deak, G., Matei, I.A., et al., 2016. *Thelazia callipaeda* in wild carnivores from Romania: New host and geographical records. *Parasites Vectors* 9, 350. <https://doi.org/10.1186/s13071-016-1628-9>.
- Morgado, A.C.T., do Vale, B., Ribeiro, P., Coutinho, T., Santos-Silva, S., De Sousa Moreira, A., et al., 2022. First report of human *Thelazia callipaeda* infection in Portugal. *Acta Trop.* 231, 106436. <https://doi.org/10.1016/j.actatropica.2022.106436>.
- Nájera, F., De Lucas-Veguillas, J., Vela, Á., López-Fernández, M., Martínez-Martínez, P., Mata-Huete, M., et al., 2020. First report of *Thelazia callipaeda* in a free-ranging Iberian wolf (*Canis lupus signatus*) from Spain. *Parasitol. Res.* 119, 2347–2350. <https://doi.org/10.1007/s00436-020-06735-y>.
- Otranto, D., Cantacessi, C., Mallia, E., Lia, R.P., 2007. First report of *Thelazia callipaeda* (Spirurida, Thelaziidae) in wolves in Italy. *J. Wildl. Dis.* 43, 508–511. <https://doi.org/10.7589/0090-3558-43.3.508>.
- Otranto, D., Cantacessi, C., Testini, G., Lia, R.P., 2006. *Phortica variegata* as an intermediate host of *Thelazia callipaeda* under natural conditions: Evidence for pathogen transmission by a male arthropod vector. *Int. J. Parasitol.* 36, 1167–1173. <https://doi.org/10.1016/j.ijpara.2006.06.006>.
- Otranto, D., Dantas-Torres, F., 2015. Transmission of the eyeworm *Thelazia callipaeda*: Between fantasy and reality. *Parasites Vectors* 8, 273. <https://doi.org/10.1186/s13071-015-0881-7>.
- Otranto, D., Dantas-Torres, F., Mallia, E., DiGeronimo, P.M., Brianti, E., Testini, G., et al., 2009. *Thelazia callipaeda* (Spirurida, Thelaziidae) in wild animals: Report of new host species and ecological implications. *Vet. Parasitol.* 166, 262–267. <https://doi.org/10.1016/j.vetpar.2009.08.027>.
- Otranto, D., Dutto, M., 2008. Human thelaziosis, Europe. *Emerg. Infect. Dis.* 14, 647–649. <https://doi.org/10.3201/eid1404.071205>.
- Otranto, D., Traversa, D., 2005. *Thelazia* eyeworm: An original endo- and ecto-parasitic nematode. *Trends Parasitol.* 21, 1–4. <https://doi.org/10.1016/j.pt.2004.10.008>.
- Papadopoulos, E., Komnenou, A., Karamanlidis, A.A., Bezerra-Santos, M.A., Otranto, D., 2022. Zoonotic *Thelazia callipaeda* eyeworm in brown bears (*Ursus arctos*): A new host record in Europe. *Transbound. Emerg. Dis.* 69, 235–239. <https://doi.org/10.1111/tbed.14414>.
- Paradžik, M.T., Samardžić, K., Živičnjak, T., Martinković, F., Janjetović, Ž., Miletić-Medved, M., 2016. *Thelazia callipaeda* – first human case of thelaziosis in Croatia. *Wien Klin. Wochenschr.* 128, 221–223. <https://doi.org/10.1007/s00508-015-0889-1>.
- Pavlović, I., Jakić-Dimić, D., Kureljusić, B., Čirović, D., Jezdimirović, N., Drobnjak, M., 2017. First occurrence of *Thelazia callipaeda* in foxes (*Vulpes vulpes* L.) in Serbia. <https://doi.org/10.15679/bjwr.v4i1.31>.
- Pimenta, P., Cardoso, L., Pereira, M.J., Maltez, L., Coutinho, T., Alves, M.S., Otranto, D., 2013. Canine ocular thelaziosis caused by *Thelazia callipaeda* in Portugal. *Vet. Ophthalmol.* 16, 312–315. <https://doi.org/10.1111/j.1463-5224.2012.01074.x>.
- Rodrigues, F.T., Cardoso, L., Coutinho, T., Otranto, D., Diz-Lopes, D., 2012. Ocular thelaziosis due to *Thelazia callipaeda* in a cat from northeastern Portugal. *J. Feline Med. Surg.* 14, 952–954. <https://doi.org/10.1177/1098612X12459645>.
- Rolbiecki, L., Izdebska, J.N., Franke, M., Iliszko, L., Fryderyk, S., 2021. The vector-borne zoonotic nematode *Thelazia callipaeda* in the eastern part of Europe, with a clinical case report in a dog in Poland. *Pathogens* 10, 55. <https://doi.org/10.3390/pathogens10010055>.
- Sargo, R., Loureiro, F., Catarino, A.L., Valente, J., Silva, F., Cardoso, L., et al., 2014. First report of *Thelazia callipaeda* in red foxes (*Vulpes vulpes*) from Portugal. *J. Zoo Wildl. Med.* 45, 458–460. <https://doi.org/10.1638/2013-0294R.1>.
- Seixas, F., Travassos, P., Coutinho, T., Lopes, A.P., Latrofa, M.S., Pires, M.D.A., et al., 2018. The eyeworm *Thelazia callipaeda* in Portugal: Current status of infection in pets and wild mammals and case report in a beech marten (*Martes foina*). *Vet. Parasitol.* 252, 163–166. <https://doi.org/10.1016/j.vetpar.2018.02.007>.
- Soares, C., Sousa, S.R., Anastácio, S., Matias, M.G., Marquês, I., Mascarenhas, S., et al., 2013. Feline thelaziosis caused by *Thelazia callipaeda* in Portugal. *Vet. Parasitol.* 196, 528–531. <https://doi.org/10.1016/j.vetpar.2013.03.029>.
- Tamura, K., Stecher, G., Kumar, S., 2021. MEGA11: Molecular Evolutionary Genetics Analysis version 11. *Mol. Biol. Evol.* 38, 3022–3027. <https://doi.org/10.1093/molbev/msab120>.
- Tasić-Otašević, S., Gabrielli, S., Trenkić-Božinović, M., Petrović, A., Gajić, B., Colella, V., et al., 2016. Eyeworm infections in dogs and in a human patient in Serbia: A One Health approach is needed. *Comp. Immunol. Microbiol. Infect. Dis.* 45, 20–22. <https://doi.org/10.1016/j.cimid.2016.01.003>.
- Vieira, L., Rodrigues, F.T., Costa, Á., Diz-Lopes, D., Machado, J., Coutinho, T., et al., 2012. First report of canine ocular thelaziosis by *Thelazia callipaeda* in Portugal. *Parasites Vectors* 5, 124. <https://doi.org/10.1186/1756-3305-5-124>.