

P239- Occurrence of *Mycobacterium avium* subsp. *paratuberculosis* in road killed

wild carnivores in Portugal



Matos Ana Cristina^{1*}, Figueira Luís¹, Martins Helena¹, Martins Manuel^{1,4}, Matos Manuela², Loureiro Filipa³, Pinto Maria de Lurdes³, Coelho Ana Cláudia³

¹School of Agriculture, Polytechnic Institute of Castelo Branco, Portugal

²IBB-Institute for Biotechnology and Bioengineering, Centre of Genomic and Biotechnology, Department of Genetics and Biotechnology, University of Trás-os-Montes and Alto-Douro,

³CECAV- Center for Animal Science and Veterinary, University of Trás-os-Montes and Alto-Douro, Department of Veterinary Sciences, Portugal

⁴CERNAS- Research Center for Natural Resources, Environment and Society - School of Agriculture Polytechnic Institute of Coimbra, Portugal
(*acmatos@ipcb.pt)

INTRODUCTION

Paratuberculosis (Johne's disease) is a chronic granulomatous gastroenteritis affecting ruminants that is caused by *Mycobacterium avium* subsp. *paratuberculosis* (Map) leading to emaciation and death. The disease is prevalent worldwide and has a significant financial impact on those affected. Cases of Map infection have been reported previously in free-ranging wild carnivores but there are limited data regarding the isolation and detection of the agent in this taxonomic order.

MATERIALS AND METHODS



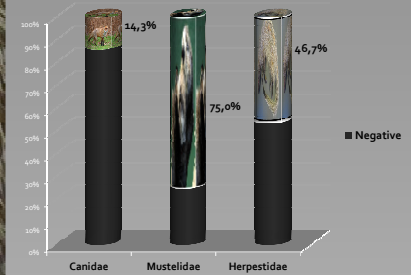
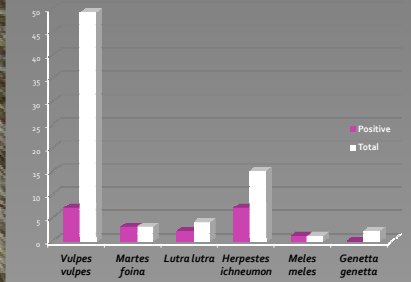
A survey to determine the occurrence of *Mycobacterium avium* subsp. *paratuberculosis* (Map) was conducted in 74 wild carnivores found dead on roads in Central Portugal from 2009 to 2012. Post mortem examination was done and tissues were collected from wild carnivores representing 4 families and 7 different species. Culture was performed and acid-fast isolates were identified by PCR and mycobactin dependency characteristics. Using a PCR-based method tissues were screened for the presence of species-specific IS900.

RESULTS

The occurrence of infected animals was 27.0% (n=20). Infection was recorded in six out of the seven studied species: 7/49 (14.3%) fox (*Vulpes vulpes*), 3/3 (100%) beech marten (*Martes foina*), 2/4 (50.0%) Otter (*Lutra lutra*), 7/15 (46.7%) Egyptian mongoose (*Herpestes ichneumon*), and 1/1 (100%) badger (*Meles meles*). Map infection was not recorded in the two genets (*Genetta genetta*) studied. Infection was found in three taxonomic families: 14.3% in Canidae, 75.0% in Mustelidae and 46.7% in Herpestidae.

In total, 666 samples were studied in culture (portions of ileocecal valve, distal jejunum and ileum, mesenteric, mediastinal, and retropharyngeal lymph nodes, spleen, brain, liver, lung, kidney) and 25 (3.8%) had positive results. Tissue samples were also studied by PCR and 40 (6.0%) had positive results. Map was grown from tissues from 8 animals. Culture positive samples came from 4 species (fox, n=5; beech marten, n=1; otter, n=1; Egyptian mongoose, n=1). PCR positive samples came from 5 species (fox, n=3; beech marten, n=2; otter, n=1; Egyptian mongoose, n=7).

In culture, infection was less associated with spleen and liver. In contrast, in PCR, infection was most frequently associated with spleen and mediastinal lymph nodes. Evidence of generalized widespread infection was found in five (71.4%) confirmed foxes, in 2 (66.7%) confirmed beech marten, in 1 confirmed otter (50.0%), in 5 (71.4%) confirmed Egyptian mongoose and in the only (100%) confirmed and studied badger.



CONCLUSIONS

This study is the first to identify that Map infection can be prevalent in wild carnivores in Portugal. According to our results there was a high occurrence of Map infection among wild carnivores and suggest that several wild carnivores could contribute to the persistence of Map infection within a wildlife complex.

